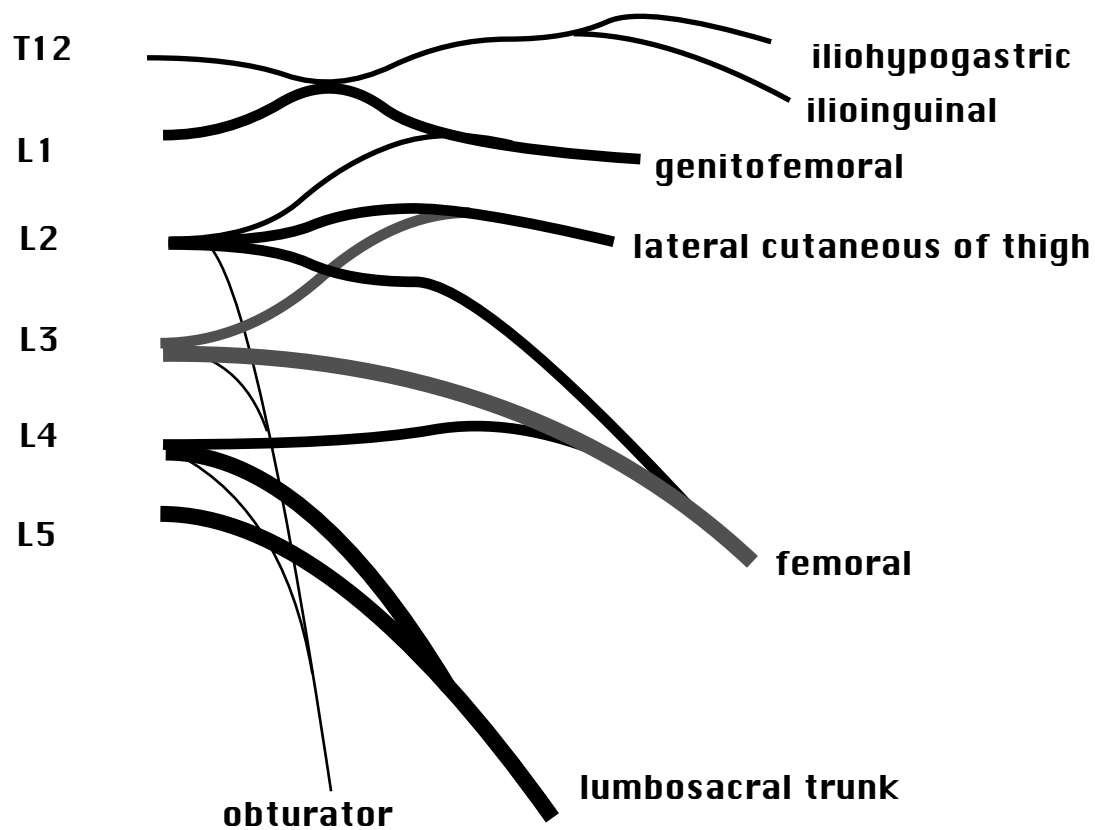


NERVES of LOWER LIMB

Remember that on leaving the vertebral column, just distal to the dorsal root ganglion, the dorsal and ventral roots unite to form the spinal nerves, which then divide into an anterior primary ramus, and a posterior primary ramus. The anterior primary rami innervate limb muscles and so we deal exclusively with them.

The ANTERIOR PRIMARY RAMI of the SPINAL NERVES unite near their origins to form plexuses - the LUMBAR PLEXUS and the SACRAL PLEXUS.

LUMBAR PLEXUS



iliohypogastric n.	skin of abdomen + buttock nr. ASIS
ilioinguinal n	skin of groin, superficial inguinal ring
genitofemoral n	skin over femoral tri., scrotum, labium majus
lat. cut. of thigh	lateral thigh
femoral n	emerges laterally from psoas
obturator	emerges medially from psoas

Note that a given spinal nerve (e.g. L5) emerges **below** the corresponding vertebra (L5) but is affected by herniation of the disc **above** (L4-L5). See sketch from (Hoppenfeld and Hutton, 1977), pp 66-67.
 e.g. L5 emerges below L5 vertebra, but is affected by herniation of L4-L5 disc.

sketch

FEMORAL nerve (L2,3,4) is the largest branch of the lumbar plexus. It descends through the psoas and gives rise to four muscle branches (generally the muscles of the anterior compartment) and three cutaneous branches:

- | | |
|-------------------------------------|----------------------------------|
| (1) ILIACUS | |
| (2) QUADRICEPS n. | all muscles of quadriceps |
| (3) SARTORIUS n. | sartorius m. |
| (4) PECTINEUS n. | adductor, floor of fem. triangle |
| | |
| (1) SAPHENOUS n. ... | medial skin of calf |
| (2) MEDIAL CUTANEOUS n. of THIGH | medial thigh |
| (3) INTERMED. CUTANEOUS n. of THIGH | front of thigh |

OBTURATOR nerve (L234) descends through the PSOAS muscle, and passes through the obturator foramen to supply external obturator and all the **ADDUCTOR** mm. except pectineus (femoral n.) and part of adductor magnus (tibial n.).

- (1) ADDUCTOR LONGUS
- (2) ADDUCTOR MAGNUS
- (3) ADDUCTOR BREVIS
- (4) GRACILIS
- (5) EXTERNAL OBTURATOR
- (6) Skin on medial side of thigh

For sketches see (Medical Research Council (Great Britain). 1986), MB 616.870754

SACRAL PLEXUS

This plexus is formed by the ventral rami of L4 & L5 (lumbosacral trunk), S1, S2 and S3. The most important branches are:

	<u>NERVE</u>	<u>INNERVATES</u>	<u>ROOTS</u>
1	Superior Gluteal N.	gluteus medius, gluteus minimus, tensor fasciae latae	L4,L5,S1
2	Inferior Gluteal n.	gluteus maximus	L5,S1,S2
4	Internal obturator + gemellus superior	Lateral rotators	L5-S2
3	Quadratus Femoris n. + gemellus inferior	Of	L4-S1
5	Piriformis n.	Thigh	S2
6	Post. Cutaneous of thigh	Buttock to pop. fossa	S1,S2,S3
7	Sciatic	L4-S3	
8	Pudendal	mm of pelvic floor, skin of scrotum, labia penis clitoris	S2-4

(emerges through greater sciatic foramen, enters lesser sciatic foramen)

Note that the piriformis is a useful landmark; superior gluteal nerves and vessels emerge above its superior border, while inferior gluteal nerves and vessels emerge below its inferior border. ((Moore, 1985).

SCIATIC n. is the thickest in the body. It leaves the pelvis via the greater sciatic foramen and emerges from under the PIRIFORMIS muscle, resting on the ISCHIUM which gives it its name (n. ISCHIADICUS). The sciatic is divided into two nerve trunks: the TIBIAL and PERONEAL, although these usually run in a common sheath until about 2/3 of way down the thigh. In some individuals the tibial and peroneal are split by the piriformis muscle, such that a piece of the piriformis, formerly called scansorius, lies between them. This may allow the peroneal n. to be pinched by the piriformis (cf McMinn & Hutchings), giving rise to 'piriformis syndrome'.

N.B. Injections into the buttock should be given into the upper lateral quadrant to avoid the sciatic nerve and its branches. (Moore, 1985).

SKETCH: sciatic and peroneal, posterior aspect, right side (Green and Silver, 1981; Medical Research Council (Great Britain). 1986).

TIBIAL n. (L5S12) About 1/3 the way down the thigh, the first muscular branches are given off to the hamstring muscles from the tibial division (extensors of the hip and flexors of knee). Note that short head of biceps is not a hamstring, and is supplied by the peroneal division. After splitting off the peroneal, the tibial nerve runs through the middle of the popliteal fossa and then passes between the heads of the gastrocnemius muscle and supplies these muscles, as well as the rest of the muscles in the posterior compartment: soleus, plantaris & popliteus, and lower down tibialis posterior, FDL and FHL.

At the level of the ankle the tibial nerve splits into the MEDIAL CALCANEAN, MEDIAL AND LATERAL PLANTAR nerves.

These nerves split off under the flexor retinaculum and enter the sole of the foot on the medial side of the ankle. They supply intrinsic muscles of the foot and the skin of the sole of the foot: the distribution of the LATERAL PLANTAR n. is similar to that of ULNAR n. in the HAND, while the medial plantar nerve corresponds to the median nerve in the hand.

SCIATICA is most commonly due to irritation or pressure of the nerve roots giving rise to the sciatic, L4-S3, and results in pain radiating down the back of the leg in the distribution of the sciatic. Commonly tested using the straight leg raise, in which the patient lies on his back and raises the straight leg. Much more rarely due to irritation of the sciatic nerve itself, in which case pressure on the sciatic nerve elicits pain.

COMMON PERONEAL (L45, S12) The common peroneal passes over the lateral head of gastrocnemius and under the tendon of biceps femoris, then winds round the head of the fibula, (where it can be palpated and exposed to injury), and then splits into the deep and superficial peroneal nerves. Cutaneous branches are the *lateral cutaneous n. of calf* and the *sural communicating nerve*.

DEEP PERONEAL (L45) The deep peroneal supplies the anterior crural muscles (the dorsiflexors of the foot -TA, EDL, EHL) and also extensor digitorum brevis, the intrinsic muscle on the dorsal surface of the foot, and a Cutaneous branches supply a small area of skin on the dorsal surface of the foot.

SUPERFICIAL PERONEAL (L5S1) This nerve runs between the peroneal muscles and extensor digitorum longus, and supplies PERONEUS LONGUS AND BREVIS.

Cutaneous branches of the superficial peroneal nerve supply skin on the dorsal surface and sides of the toes, and on the anterolateral surface of the ankle.

DAMAGE TO COMMON PERONEAL is not uncommon. It leads to 'footdrop' (paralysis of dorsiflexors, so the foot slaps on the ground immediately after heelstrike), loss of eversion (paralysis of peronei), and loss of sensation over the dorsal aspect of the foot (mostly superficial peroneal).

CUTANEOUS INNERVATION

We now know the areas of skin innervated by different cutaneous nerves, and can map out the skin of the lower limb according to its innervation.

SLIDE

cf Last 5 p40-42

DERMATOMES

We also know which spinal roots supply these cutaneous nerves, and from this we could work out the DERMATOMES - i.e. the area of skin supplied by the spinal nerves. In fact, this information comes from clinical studies where spinal roots have been severed; and is clinically relevant in cases where intervertebral discs are damaged and exert pressure on spinal roots.

Remember that we can define a ventral or pre-axial line and a dorsal or post-axial line for the upper and lower limb. This is straightforward in the embryo, but distorted in the adult due to lateral rotation of the arm and medial rotation of the leg, so that the lines, originally on the mid-ventral and mid-dorsal surface, are twisted so that the preaxial line lies medially in the leg. These lines separate two discontinuous regions of dermatomes, with the upper segments on the anterior aspect of the leg, and lower segments on the posterior aspect:

sketch

sketch

e.g.

Last 5 p42

Note that in the groin, we have T12 and L1 over the symphysis pubis, and then go back to the perineum, innervated by S2. So L2, L3, L4, L5 and S1 are all displaced peripherally onto the limb (Joseph p118b).

MYOTOMES

One could also speak of adult MYOTOMES, i.e. the musculature innervated by a single spinal nerve - these are relatively clear in the embryo, but not in the adult. However, knowledge of which muscles are supplied by the spinal roots is just as important as knowledge of the dermatomes. But rather than remembering the segmental innervation of each muscle, remember that

- 1 most muscles are supplied equally from two adjacent segments
- 2 muscles with the same action at a joint are supplied by the same segments
- 3 the segments controlling more distal joints lie lower in the cord:

A very rough guide is given by Last (7 p 29):

HIP	KNEE	ANKLE
2 Flex		
3 _____	3 Extend	
4 Extend	4 _____	4 Dorsiflex
5	5 Flex	5 _____
	1	1 Plantarflex
		2

see also: (Hoppenfeld and Hutton, 1977).

References

- Green, J.H., Silver, P.H.S., 1981. An Introduction to Human Anatomy. Oxford U.P., Oxford.
- Hoppenfeld, S., Hutton, R., 1977. Orthopaedic neurology : a diagnostic guide to neurologic levels. Lippincott, Philadelphia, pp. xii, 131.
- Medical Research Council (Great Britain). 1986. Aids to the examination of the peripheral nervous system. Baillière Tindall, London ; Philadelphia, pp. 61.
- Moore, K.L., 1985. Clinically oriented anatomy. Williams & Wilkins, Baltimore, pp. xiv 1101.